

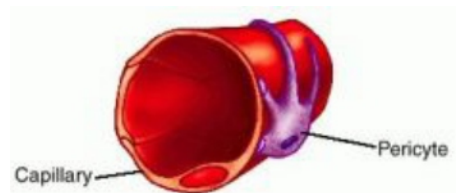
Hemangiopericytoma

WHEN THE DIAGNOSIS IS HEMANGIOPERICYTOMA...

The hemangiopericytoma is a common tumor in the dog generally arising on the limbs and appearing as a round nodule. It derives from pericytes associated with blood vessels (see below) and, at least in some cases, involves a chromosome abnormality (usually an extra or an absent chromosome) in the original cancerous pericyte. Hemangiopericytomas can appear bald, pigmented or even ulcerated.

What is a Pericyte?

Consider that everyone began life as a single cell. This cell divided over and over and became many cells. As time continued, we became groups of different types of cells. Eventually we became embryos, fetuses, and finally infants with complete organ systems and different tissues all derived from one original cell. During the course of this amazing development, some cells do not specialize fully into specific tissues. They stay "undifferentiated" and can in the future specialize into whatever type of cell our body might require at that time. We have cells throughout our bodies that simply "stayed put" at different stages of embryonic development. Pericytes are such cells. A pathology instructor once described the pericyte as perhaps not the Adam and Eve of our bodies but more like Abraham.



What is a Hemangiopericytoma?

A hemangiopericytoma is a tumor arising from pericytes associated with blood vessels. Instead of forming a useful tissue, these pericytes form tumors because improper cell division has left them with chromosome damage.

Is it Cancer?

The hemangiopericytoma does not spread through the body in the way one normally thinks of cancer. It does however tend to recur at the site of its original removal. When it recurs, it tends to grow back more deeply rooted and more difficult to remove than it was in its original form. If left alone it will continue to grow inexorably over usually years until it invades a part of the body that does not have extra space to allow a tumor (usually the chest cavity is the closest such area.)

If left alone, this tumor eventually becomes inoperable, disfiguring, and lethal though generally this takes years.

What are the Treatment Options?

- **Radiation therapy**

The hemangiopericytoma is responsive to radiation therapy. This means that the cure rate after radiotherapy is 80-90%. Only the tumor site receives radiation in this type of therapy so the patient does not become ill though the area of radiation exposure will probably lose the ability to grow hair. Effective radiation therapy unfortunately requires 15-18 treatments and the total cost in our area runs \$4000-\$4500. For radiotherapy to be effective, the tumor must first be surgically removed without visible remaining tumor present; otherwise the tumor is will be too big to respond.

- **Leave tumor alone for now and attempt another surgical removal when it recurs.**

One option is to wait and see if the tumor regrows (it usually does). When it regrows, it can be re-removed; however, when it re-grows, it is usually more difficult to remove. Every time it is removed, it re-grows more invasively making the next surgery more difficult. If a second surgery removes the visible portions of the tumor successfully, radiation therapy can again be considered as above with similar success rate.

- **Leave tumor alone and allow it to recur without treatment**

This may be a realistic option for an elderly patient as the hemangiopericytoma typically requires 6-12 months to grow back and longer to become disfiguring or invasive. For a younger patient, this is probably a poor option as the tumor will eventually become, as mentioned, inoperable, disfiguring, and lethal.

- **Allow the tumor to recur then amputate the limb**

This may seem extreme but it certainly resolves the lethal aspect of the tumor in a curative manner. The hemangiopericytoma does not spread distantly in the body so amputation of the limb achieves cure and does so far less expensively than radiotherapy, though amputation is a major surgery and can still be expected to cost \$2000-\$3000 in our area.

- **Metronomic Chemotherapy**

Metronomic chemotherapy involves the use of chemotherapy drugs at very small doses daily or at least much more frequently than the traditional chemotherapy protocols would have them used. For incompletely removed hemangiopericytomas, the goal of metronomic chemotherapy is to hamper the regrowth of the remaining tumors blood supply. The most common protocols use a combination of cyclophosphamide and pyroxicam. This type of treatment is not generally helpful when grossly visible tumor is present but is best for preventing the re-growth of a tumor after all its visible portions have been removed.

If your dog has been diagnosed with a hemangiopericytoma, you may want to be referred to an oncologist for the most up to date recommendations. Veterinary oncologists are certified by the American College of Veterinary Internal Medicine. To locate an oncologist in your area visit:

www.perseusfoundation.org/new-petowner/onc_locate.cfm



Mar Vista Animal Medical Center

3850 Grand View Blvd., Los Angeles, CA 90066 • (310) 391-6741 • Fax: (310) 391-6744

Information on additional pet care topics can be found on our world wide web site:

<http://www.marvistavet.com>